

Original Contribution

Performance comparison of lung ultrasound and chest x-ray for the diagnosis of pneumonia in the ED[☆]

Jean-Eudes Bourcier, MD^{a,*}, Julie Paquet, MD^a, Mickael Seinger, MD^a, Emeric Gallard, MD^a, Jean-Philippe Redonnet, MD^a, Fouad Cheddadi, MD^a, Didier Garnier, MD^a, Jean-Marie Bourgeois, MD, PhD^b, Thomas Geeraerts, MD, PhD^c

^a Emergency, Anesthesiology and Critical Care Department, Lourdes Hospital, Lourdes, France

^b CFFE (Centre Francophone de Formation en Echographie) and, Centre Médical Delta, Nîmes, France

^c Anesthesiology and Critical Care Department, Toulouse University Hospital, University Toulouse 3 Paul Sabatier, Toulouse, France

ARTICLE INFO

Article history:

Received 12 September 2013

Received in revised form 25 September 2013

Accepted 1 October 2013

ABSTRACT

Objective: The aim of our study was to assess the potential of bedside lung ultrasound examination by the attending emergency physician in the diagnosis of acute pneumonia.

Material and Methods: This observational single-center study was conducted between January 2010 and June 2012 in the emergency unit of a general hospital, and analyzed 144 adult patients. The ultrasound examination was performed by one of five trained emergency physicians, and a chest radiograph interpreted by a radiologist. The primary end point was the diagnosis of hospital discharge.

Results: We found a sensitivity of 0.95 for the ultrasound examination against 0.6 for radiography ($P < .05$). The negative predictive value was 0.67 against 0.25 for radiography ($P < .05$).

Conclusion: These results exhort to promote the use of thoracic ultrasound in the first-line diagnosis of pneumonia.

© 2013 Elsevier Inc. All rights reserved.

1. Introduction

Acute pneumonia is the first cause of mortality related to infectious disease in Western countries, and on major cause of severe sepsis and septic shock [1]. However the diagnosis of acute pneumonia is often difficult in the emergency setting, as clinical, biological, and imaging sign are not specific [2].

International guidelines recommend the use of chest x-ray as first line examination, despite its low sensitivity and specificity [3]. Thoracic computed tomography (CT) scan, although considered as the gold standard, is often not performed and involves an important exposure to ionizing radiations, limiting its use to difficult cases.

Lung ultrasounds have shown a growing interest during the last few years in the diagnosis of pleural effusions, pneumothorax, pneumonias, or pulmonary contusions [4–6]. Most studies were realized in patients from intensive care setting. The results are so encouraging that in some units, chest x-rays have been replaced by lung ultrasounds in the follow-up of the patients [7,8]. In the emergency department (ED), the use of lung ultrasounds in the diagnosis of acute pneumonia has been studied in only a few studies [9]. Because of the bedside use of the ultrasound units, result can be

immediately available preventing any delay in the diagnosis process. Moreover, its realization by the attending emergency physician could allow a substantial time-saving for the establishment of the diagnosis and consequently reduce the length of stay at the ED. However, the reliability of ultrasound diagnosis of acute pneumonia by ED physician must be confirmed before generalization of its use.

The aim of this study was to assess the potential of bedside lung ultrasound examination by the attending emergency physician in the diagnosis of acute pneumonia.

2. Material and methods

The study protocol has been approved by the local Ethics Committee of our institution (PV 27613).

In this single-center study, patients were included in the ED setting if presented the following criteria:

Age 18 years and older, suspected of infectious acute pneumonia with at least three of the following items: tympanic temperature equal or higher than 38°C, cough, dyspnea, heart rate higher than 100 beats per minute, saturation of oxygen lower or equal to 92% in ambient air.

Five emergency physicians trained in sonography were involved in the study. The total staff of ED physicians was 10 during the inclusion period. Training was performed in a qualified sonography center according to the American College of Emergency Physician's recommendations. It consisted in 2 days of theoretical formation alternating with practical ultrasounds sessions in groups of 3 people. Trainers of

[☆] Conflict of interest: The authors have no conflict of interest to disclose.

* Corresponding author. Pôle Anesthésie-Réanimation- Urgences Hôpital de Lourdes, 2 avenue Alexandre Marqui 65100 Lourdes, France.

E-mail address: je.bourcier@gmail.com (J.-E. Bourcier).

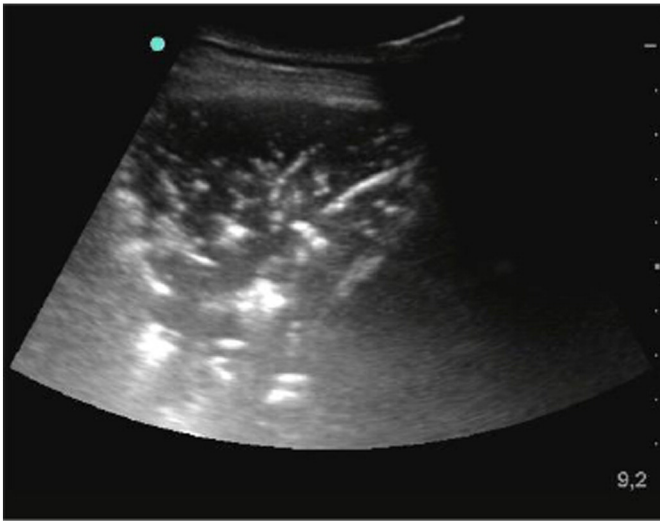


Fig. 1. Typical lung ultrasound of alveolar syndrome.

the center provided companionship for sonography knowledge maintenance and improvement, and in reading of digital ultrasound images [10]. The lack of a trained emergency physician in ultrasound was a criterion for non-inclusion.

The emergency physician performed the lung ultrasound examination at the bedside immediately after the clinical examination (Portable ultrasound device SONOSITE M TURBO, Bothell, WA, USA). The ultrasound exploration led to a written report as well as the recording of images. The technique of ultrasound exploration was in accordance with international guidelines, and consisted in examination of 8 areas from the chest wall, by means of a convex 3.5 MHz transducer. Whenever possible, it was recommended to sit the patient to facilitate the exploration of the posterior fields. Otherwise one could turn the patient to the opposite side.

The presence of a unilateral or a bilateral alveolar-interstitial syndrome was necessary to retain the ultrasound diagnosis of pneumonia. The alveolar-interstitial syndrome (Fig. 1) was defined as the disappearance of the pleural line associated with aeric or water bronchograms within an image of tissue echogenicity [11]. This image could be to a “liver-like” lung aspect with or without effusion, corresponding to an outbreak of acute lobar pneumonia (Fig. 1). Alveolar syndrome and atelectasis could be differentiated based on the dynamic aspect of bronchograms, this latter being increased during the inspiration in case of alveolar syndrome.

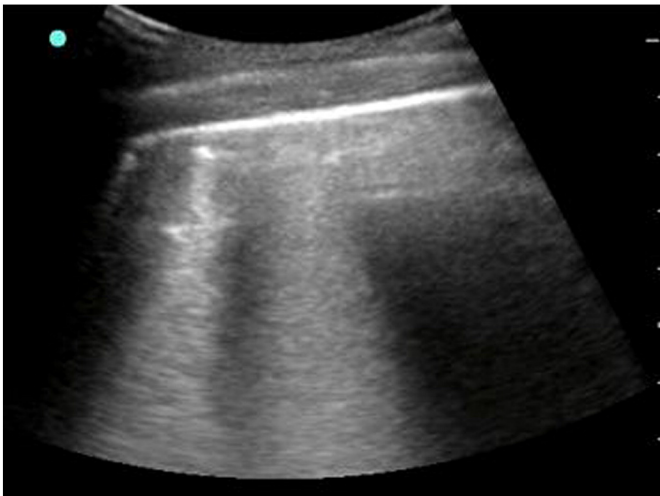

Fig. 2. Typical lung ultrasound of interstitial syndrome.

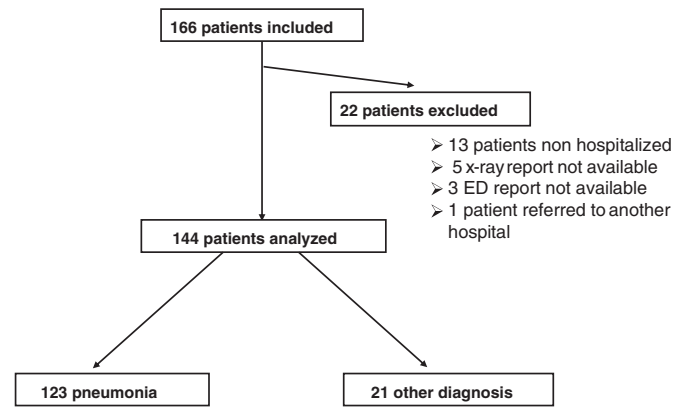


Fig. 3. Flow chart.

Interstitial syndrome (Fig. 2) was defined by the presence of more than 3 B lines artifacts (rings down) by field of examination: vertical hyperechoic artifacts spreading up to the edge of the screen, moving with respiratory movements. These artifacts can be physiologically present at the lung base.

The usual standard of care was not modified by the present study protocol and each patient underwent a chest x-ray after the lung ultrasound examination and subsequently referred to the appropriate health care service.

The final diagnosis was performed by an independent senior expert, based on the examination of the complete medical chart including initial clinical findings, emergency laboratory test, chest x-ray data, and the results of thoracic CT scan if available.

The primary end point was the respective diagnosis performances of lung ultrasound and chest x-ray to a correct final diagnosis.

The secondary end point was the concordance of lung ultrasound and chest X-ray with thoracic CT scan when performed. The thoracic CT scan was considered as the gold standard method.

3. Statistical analysis

Continuous variables were expressed as means \pm SD and categorical data as numbers (percentages). The performance of each examination was expressed as sensitivity, specificity, positive and negative predictive values, and then compared by χ^2 test.

A value of $P < .05$ was considered as a statistical significance. A population size calculation has been performed based on a preliminary study performed in our units, and found the need to include at least 120 patients to allow detection of a difference in sensitivity of 25% between chest x-ray and lung ultrasound for a sensitivity of the chest x-ray of 70% with a β risk of .2 and α of 0.05.

4. Results

One hundred sixty-six patients were included from January 2010 to June 2012. Twenty-two patients were secondarily excluded, resulting in 144 finally analyzed patients. (Fig. 3)

Table 1
Sensitivities, specificities, positive and negative predictive values for lung sonography and chest x-ray for the diagnosis of acute pneumonia

	Sonography	Chest x-ray	
Sensitivity	0.95	0.60	$P < .01$
Specificity	0.57	0.76	$P = .09$
Positive predictive value	0.93	0.93	ns
Negative predictive value	0.67	0.25	$P < .01$

Table 2

Respective performance of lung ultrasonography and chest x-ray for the diagnosis of acute pneumonia according to the delay from the onset of clinical signs

	Positive sonography	Positive chest x-ray	P
Signs <24 h, n = 44	43 (76%)	13 (23%)	< .001
Signs >24 h, n = 79	74 (93%)	61 (77%)	.003

The study population included 72 men and 72 women aged 77.6 ± 15.2 years. The diagnosis of pneumonia was retained after hospitalization for 123 of them. The respective diagnosis performances of lung ultrasound and chest x-ray, and their comparison are shown in Table 1.

Nine patients who were diagnosed with pneumonia after lung ultrasound finally had another diagnosis: 4 patients with sepsis of other origin, 2 patients with pulmonary embolism, 1 with acute respiratory distress syndrome, 1 with pulmonary fibrosis and one with acute anemia from gastric origin. For these patients, chest x-ray led to a false positive in 5 out of 9 cases.

Among the 49 cases with negative chest x-ray, final diagnosis of pneumonia was made 43 times by lung ultrasound.

Analysis of patients with pneumonia signs for less than 24 hours results are presented in the Table 2. In the two cases the chest ultrasound was more accuracy than chest x-ray. However there are many more pneumonias detected by ultrasound in the first 24 hours of the affection.

Among the 29 patients who underwent a CT scan (the gold standard method) due to difficult diagnosis (Table 3), 23 had pneumonia. In those patients, ultrasound accuracy was 100% (23 correct detection of pneumonia), whereas chest x-ray accuracy was only 52% (12 correct diagnosis among 23).

5. Discussion

The present study is one of the first to show a potential interest for the lung ultrasound compared to standard care patients for the diagnosis of acute pneumonia in non-selected ED patients. This study reveals a significantly higher sensitivity of lung ultrasound for the diagnosis of acute pneumonia compared to chest X-ray (95% vs 60%, *P* < .01). Interestingly lung ultrasound appears to be particularly more effective than chest X-ray when pneumonia is evolving for less than 24 hours. Moreover, when CT scan was performed due to difficult diagnosis, the performance of lung ultrasound for acute pneumonia diagnosis was 100%.

These results suggest a higher performance of lung ultrasound compared to chest x-ray, especially for early and difficult diagnosis of acute pneumonia.

Our results are comparable with those of previously published studies conducted in ED for the diagnosis of pneumonia, which found a sensitivity of 97–98% for lung ultrasounds vs. 67–75% for radiography [12–14]. In these studies like in ours, the primary end point was the final diagnosis at patient discharge. Lung ultrasound was compared with chest x-ray, CT scan remaining the gold standard in case of discrepancy between the two examinations; but only one expert had the ultrasound training, explaining the relatively small number of patients included in these studies. Indeed, our study is the first to our knowledge in which half of the emergency physicians staff was trained for lung ultrasound and, therefore, can recruit patients.

Table 3

Respective performance of lung ultrasound, chest x-ray in the diagnosis of acute pneumonia according to the CT scan diagnosis

Pneumonia on thoracic CT scan	Positive sonography	Positive chest x-ray	P
N = 23	23	12	< .01

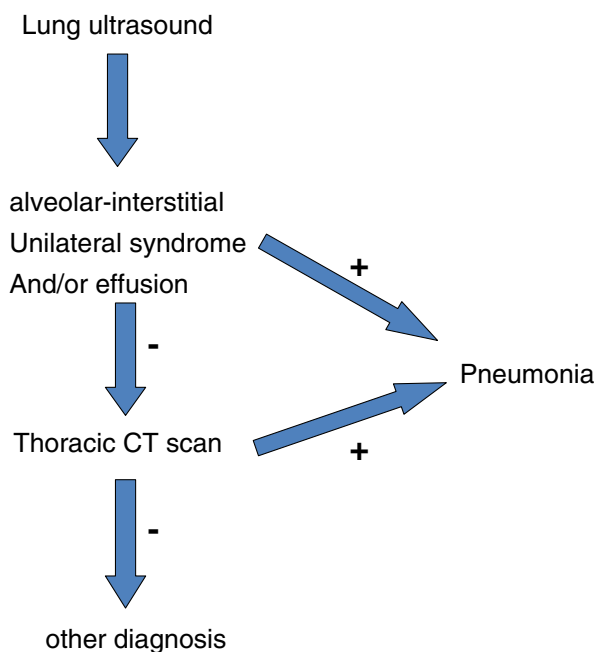


Fig. 4. Decision making algorithm in the diagnosis of acute pneumonia in the ED setting.

The main limitation of the present study lies in the fact that the primary end point chosen, in this case the final diagnosis made by the clinician after hospitalization is also based on additional tests, including ultrasounds and the initial radiograph. To overcome this bias, we should have used the results of CT as a primary end point, which in terms of availability and irradiation is not justifiable. That's probably why it was also chosen in studies similar to ours [12–14].

Of the 144 patients, 9 false-positive examinations were observed for ultrasound, mainly due to sepsis from other origin or non-infectious pulmonary disease.

A possible option to limit false-positive rates could be to associate lung ultrasound to transthoracic cardiac ultrasound evaluation as done in the work of Silva et al with dyspnea in critical care practice [15], or to search for poplito-femoral thrombosis as shown in the BLUE protocol proposed by Lichtenstein [16,17].

Lung ultrasound performance is probably very good at detecting superficial pneumonia, it remains however poor at detecting deep alveolar lesions. The 6 false-negative results observed in this study is probably related to deep alveolar infection.

6. Conclusion

This study shows a clear superiority of lung ultrasound performed by a trained ED physician over the chest x-rays for the diagnosis of acute pneumonia. Given the ultrasonography performance for the diagnosis of acute pneumonia, lung ultrasound could replace chest x-ray as the first-line imaging investigation. In difficult cases (deep lesion) or in case of negative ultrasound, thoracic CT scan could be performed as suggested by a proposed decision-making algorithm for acute pneumonia diagnosis in the ED setting (Fig. 4).

References

- [1] Brun-Buisson C, et al. EPISEPSIS: a reappraisal of the epidemiology and outcome of severe sepsis in French intensive care units. *Intensive Care Med* 2004;30(4): 580–8.
- [2] Mayaud C. Pneumonia is the leading cause of death of infectious origin. *Rev Prat* 2011;61(8):1061–3.
- [3] Niederman MS, et al. Guidelines for the management of adults with community-acquired pneumonia. Diagnosis, assessment of severity, antimicrobial therapy, and prevention. *Am J Respir Crit Care Med* 2001;163(7):1730–54.

- [4] Gehmacher O, et al. Ultrasound imaging of pneumonia. *Ultrasound Med Biol* 1995;21(9):1119–22.
- [5] Benci A, et al. Sonographic diagnosis of pneumonia and bronchopneumonia. *Eur J Ultrasound* 1996;4(3):169–76.
- [6] Birnholz J. Chest wall and lung surface viewing with ultrasound. *Chest* 1988;94(6):1275–6.
- [7] Lichtenstein D, et al. Comparative diagnostic performances of auscultation, chest radiography, and lung ultrasonography in acute respiratory distress syndrome. *Anesthesiology* 2004;100(1):9–15.
- [8] Gazon M, et al. Agreement between lung ultrasonography and chest radiography in the intensive care unit. *Ann Fr Anesth Reanim* 2011;30(1):6–12.
- [9] Volpicelli G, et al. Bedside lung ultrasound in the assessment of alveolar-interstitial syndrome. *Am J Emerg Med* 2006;24(6):689–96.
- [10] American College of Emergency. P., Emergency ultrasound guidelines. *Ann Emerg Med* 2009;53(4):550–70.
- [11] Volpicelli G, et al. International evidence-based recommendations for point-of-care lung ultrasound. *Intensive Care Med* 2012;38(4):577–91.
- [12] Parlamento S, Copetti R, Di Bartolomeo S. Evaluation of lung ultrasound for the diagnosis of pneumonia in the ED. *Am J Emerg Med* 2009;27(4):379–84.
- [13] Cortellaro F, et al. Lung ultrasound is an accurate diagnostic tool for the diagnosis of pneumonia in the emergency department. *Emerg Med J* 2012;29(1):19–23.
- [14] Zanolletti M, Poggioni C, Pini R. Can chest ultrasonography replace standard chest radiography for evaluation of acute dyspnea in the ED? *Chest* 2011;139(5):1140–7.
- [15] Silva S, et al. Usefulness of cardiothoracic chest ultrasound in the management of acute respiratory failure in critical care practice. *Chest*; 2013 .
- [16] Lichtenstein D. Lung ultrasound in acute respiratory failure an introduction to the BLUE-protocol. *Minerva Anesthesiol* 2009;75(5):313–7.
- [17] Lichtenstein DA, Meziere GA. Relevance of lung ultrasound in the diagnosis of acute respiratory failure: the BLUE protocol. *Chest* 2008;134(1):117–25.